Immediate cut hair translocation to the intergluteal fold in the hairdressers shop – another link to pilonidal sinus disease

Dietrich Doll[1,2,6], Dirk Wilhelm[3], Andreas Ommer[2,4], Kristina Albers[2], Hanna Mordhorst[2], Igor Iesalnieks[2,5], Pantelis Vassiliu[6], Markus M Luedi[2,7]

ORIGINAL ARTICLE

1. Department of Procto-Surgery, St. Marienhospital Vechta, Academic Teaching Hospital of the Medizinische Hochschule Hannover, Vechta, Germany
2. Pilonidal Research Group, Vechta, Germany
3. Klinik und Poliklinik für Chirurgie, Klinikum rechts der Isar der TU München, Germany
4. End-und Dickdarm-Zentrum Essen, Essen, Germany
5. Städtisches Klinikum Bogenhausen, München, Germany
6. 4th Surgical Clinic, Attikon University Hospital, Athens, Greece
7. Department of Anaesthesiology and Pain Medicine, Inselspital, Bern University Hospital, University of Bern, Bern, Switzerland
8. Directorate for Trauma and Burns, Chris Hani Baragwanath Academic Hospital, University of Witwatersrand Medical School, Johannesburg, Republic of South Africa

Corresponding author: Professor Dr. med. Dr. phil. Dietrich Doll, Department of Procto-Surgery, St. Marienhospital Vechta, Marienstr. 6-8, D-49377 Vechta, Germany. Telephone: +49 4441 99 1240. Cell phone: +49 1723 58 5454. Fax: +49 4441 99 1250. e-mail: ddoll@gmx.de

ABSTRACT

Introduction: The genesis of pilonidal sinus disease is still disputed, but there is mounting evidence that occipital cut hair may play a major role, with the folliculitis theory losing ground. Translocation of cut hair from the head to the lower back has not been proven so far.

Methods: Eight men were asked to undress their upper body immediately following a dry haircut. A large layer of sticky transparent plastic sheeting was applied to their chest and back, then removed and placed on millimeter scale paper, fixing all hairs in position. Cut hairs were counted and the totals were transferred to Excel matrix datasheets.

Results: Despite protective measures taken during haircuts, all customers had cut hair on their upper body (chest and back) (38-630 hair fragments; median 325), with the majority of hairs (62%) located on the back. Cut fragments were mostly found close to or within the sweat crest, and were also present in the lower back.

Conclusion: Any haircut results in large numbers of sharp hair fragments on the upper body despite the use of a protective gown and an elastic paper collar. This sharp hair slides down the posterior sweat crest towards the nates and into the intergluteal fold, where it can inject itself into the healthy skin. Young patients should shower or take a bath following a haircut to reduce their intergluteal hair load. It is highly likely, but not yet proven, that the frequent exposure to a large number of cut hair fragments at a certain age leads to pilonidal sinus disease. If we solve this question, then prevention of pilonidal sinus would be possible.

Keywords: pilonidal sinus, sharp cut hair, intergluteal pilonidal sinus disease, axial hair strength, occipital hair, barber, pathogenesis.

ISSN: 2207-7537

Reviewers: ABC, DEF, HIJ

Date of submission: 14/03/2019

INTRODUCTION

Multiple theories have been proposed for the generation of pilonidal sinus disease (PSD). One hundred years ago it was thought that midline location of the disease was proof of congenital origin [1]. Skin remnants, it was suspected, were drawn into the subcutaneous tissue during faulty closure of the skin overlying the neural tube, promoting hair growth [2]. But pathologists were unable to find hair roots and sweat glands in the sinus nest [3], so the hair must have been introduced into the skin by another mechanism. A remnant vestigial gland (as more often found in birds) was proposed to be the reason [4], but later abandoned, as was the regular connection from/to the neural tube [5].

During World War II, Buie postulated that PSD was acquired by 26,000 young soldiers due to typical war duties such as driving jeeps with hard seats on bad roads [6], and the repetitive trauma theory was born. Although Favre was able to prove 20 years later that driving and hygiene were not associated with higher PSD incidence [7], the theory was practical, and continued to be used worldwide. PSD incidence, which is higher in the military, continued to rise despite the end of the war [8], and is still rising in the peaceful northern European countries [8,9].

Microscopy of the intergluteal skin revealed larger pores and sometimes keratin within these pores in the 1950's, and so folliculitis of plugged hair follicles was postulated, with inflamed hair follicles giving way to insertion of fully grown hairs into the skin [10]. It was Bascom who postulated that "[Hair] now appears to be a secondary invader." He cites Lamke, Larsson and Nylen as proof, but these three authors just mentioned that "I found in this material that young people more commonly suffer from Pilonidal Sinuses. This is difficult to explain but might depend on a greater activity of their sweat and sebaceous glands" [11]. This is far from proof, but nevertheless echoed as proof of the folliculitis-theory.

Although most PSD patients do not report signs and symptoms of folliculitis, and most show no telogenic hair in the glabella sacralis, the folliculitis theory was hard to abandon. A bulky hair root end disables full hair injections into the deeper skin (Figure 1), while in the sinus predominantly rootless hairs are found by some [12]. Recently, Bosche has shown that stiffer hair predisposes to PSD [13]. Recent findings combining clinical, statistical and criminal biology methods have shown that occipital hair is part of the hair found in the sinus nest [14]. Fragments shorter than 1.5 cm can be found, most cut at both ends. If cut hair is present, where does it come from? The trail from head to sinus – the path of translocation – has to date not been demonstrated.

Our study aimed to show the amount and path of cut hair sliding from the head downwards. We hypothesized that hair slides down the back shortly after a haircut and accumulates in the midline, which runs towards the intergluteal fold.

METHODS

Eight men from northern Germany were approached in a hairdresser's shop and invited to take part in the study (Table 1). Informed consent was obtained. A dry haircut was performed using regular protective measures (a protective gown and elastic paper neck collar for the client). Following the dry haircut, while neck collar and protective gown were still on, cut hair was removed from the neck and face using either a brush or a hairdryer. The paper collar and gown were then removed successively.

Clients were asked to undress their upper body by opening and removing their shirt. If a T-shirt was worn, the client was asked to remove it without turning it inside out above the head. Care was taken not to touch the head.

Next, 45x45 cm sheets of a 45x75 cm sticky transparent polypropylene plastic (folia Bucheinbandfolie, Max Bringmann KG, Nürnberg, Germany) were applied onto the back and the front upper body for a few seconds, and the Vertebra prominens (C7) and spine (posterior body application) as well as the jugulum and umbilicus (anterior body application) were marked on the sheet. The plastic sheet, which was removed very slowly to retain its shape and not to depilate hair, was placed onto paper with a millimeter scale, fixing all hairs in position. In separate small area testings before, we could show that all cut hair fragments were taken up from the skin if a fresh drape was used.

Every hair was judged to be either a cut hair or depilated hair from the extraction site; the depilated hairs could be distinguished by their roots. We did not see any hairs suspected of being depilated without roots. Only cut hair was counted and extracted hair – if present at all - was discarded. Totals were transferred to Excel matrix data sheets.

Statistics

Excel (Microsoft Office Professional 2007 from Microsoft Corporation, Redmond, WA, USA) and GraphPad Prism (Graph Pad Prism for Windows, Version 5.02, Dec 2008, from GraphPad Software Inc., La Jolla, CA, USA) were used to protocol, process, and analyze data as well as to design graphics. Values are given using mean, median and range. Significance was set at $p < 0.05$.

Figure 1: Back with applied sticky drape in situ. Vertebra prominens (vertebra C7; black circle) and spine are outlined with permanent marker.

RESULTS

Customers had cut hairs on their upper body in the back and the front (range 38-630 hair fragments, median 325), with the majority of hairs (62%) located on the back (Table 1). There were no customers without cut hair fragments on their skin. Cut fragments were mostly found high up on the neck and at the base of the neck (Figure 2). In total, 2,486 cut hair fragments were counted.

As can be seen in Figure 2, hair is found in the largest quantities in the neck and in the upper back. The greater the distance from C7, the fewer hairs are present on the back skin immediately after haircut. It is most likely though that remaining cut hair on the head (unmeasured) and the documented amount of cut hair will follow gravity along a path downwards towards the gluteal fold.

Figure 3 demonstrates the hair distribution over the back in a horizontal way. Most hair can be found close to or within the sweat crest (midline). The further one examines the sides towards the shoulders, as fewer cut hair can be detected. Please note that this figure depicts the hair distribution on the back (C7 downwards).

Patient	total	back [n]	front [n]
1	71	39	32
2	296	87	209
3	38	8	30
4	630	457	173
5	400	236	164
6	354	236	118
7	70	16	54
8	627	467	160
total	2486	1546	940
max	630	467	209
min	38	8	30
mean	311	193	118
sd	240	189	70
median	325	162	139

Table 1: Cut hair counts from the back and front of the upper body immediately following a dry haircut (N=8 participants)

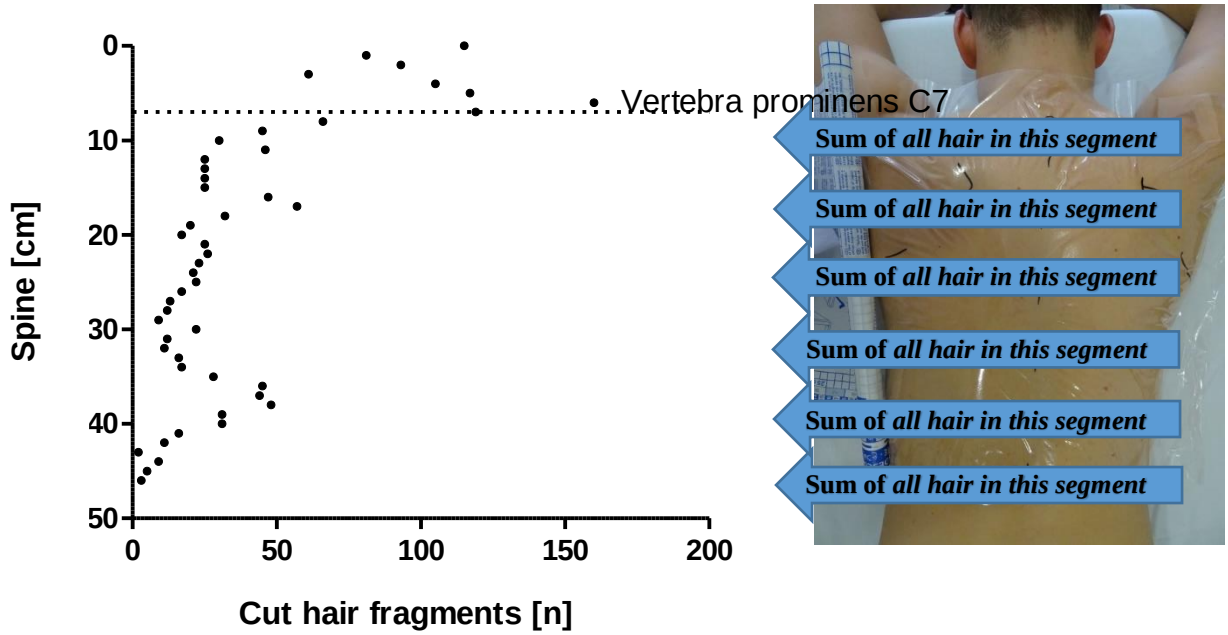

Figure 2: Number of cut hair fragments at the back (dorsum) between the base of neck C7 (Y=5cm¸top of the graph) and the lumbar spine (Y=50 cm; base of Y-axis; N=8 participants). Each dot in the left sided graph describes the numbers of cut hairs found in a segment from right-to-left-side on the body 1 cm wide.

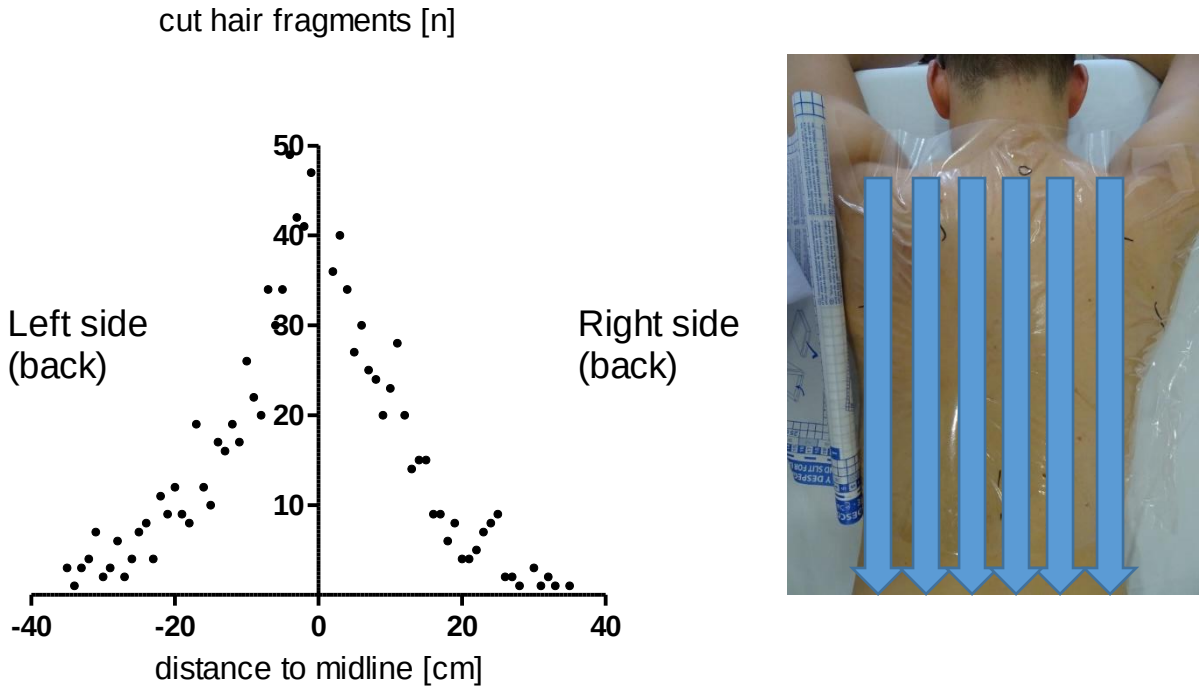

Figure 1: Number of cut hair fragments at the back (dorsum) in and around the midline (N=8 participants). Each dot in the graph describes the numbers of cut hair found in a neck-to-lumbar segment 1 cm wide on the body.

In anterior tests, there was less cut hair per hair cut to be counted, and this was distributed more evenly between the shoulder front area (Suppl. Fig. 4). The midline to both sides distribution of cut hair on the breast and belly was analyzed as well in the same patients (Suppl. Figure 5). As can be seen, cut hair is found less often anteriorly than on the back. Furthermore, the midline focus is much less pronounced than in the back (as compared to Figure 3).

DISCUSSION

It has been suspected that occipital hair travels down to the intergluteal fold. With this small study we could show that male customers leave the hairdressers with the skin of their upper body covered in small hair fragments, despite protection with a gown and collar. Thus, not only is the hairdresser at risk of penetration by cut hairs [15], but the customers are as well.

The number of hair fragments on the skin varied by a factor of 7. Electric razors produce more hair fragments than scissors, and short haired people are exposed to more fragments than those with long cut hair over time. This is simply due to short haircuts needing a haircut more often to stay trimmed. The cut hair fragments thus are shorter and more lightweight and fall with gravity. They therefore adhere to skin more easily than heavier long hair fragments. This is congruent with the findings of

Bosche in 2017, who found hair lengths of 5 mm and less were over represented in hair nests of 20 pilonidal sinus patients [12]. Dry cuts are associated with more single cut hairs, while hair fragments stick together in wet cuts, and the latter penetrate less. Repetitive dry haircuts are commonplace in the military, as is pilonidal sinus disease in the younger soldiers. It is possible that frequent exposure to dry haircuts, rather than jeep driving, is the reason for the higher incidence in soldiers [8, 9, 16]. Nevertheless, pilonidal incidence is not higher in the elderly military men despite wearing short hair, so recurrent short haircuts may pose more a risk to a younger cohort than to the elder ones. Changes to skin have been proposed, but so far not validated [17].

How such substantial amounts of hair are left on the skin's surface is not clear. The hairs could pass through an opening at the neck, if the paper collar is not tight enough; they could pass through the dorsal opening of the protective gown, or they could pass directly through the client's clothing. This mechanism must be fast, as most hair fragments on the back and front are present immediately following the haircut.

The limitations of our small study are that we studied only dry haircuts in a northern German male-only cohort. We did not check whether the customers already carried cut hair fragments on their skin before arrival. Furthermore, we did not count the number of cut hair fragments still present on the head following the haircut. If these additional cut hairs are taken into consideration, the number overall (currently n=139 median) will increase further. This will likely contribute to a more central (close to the midline) distribution of hair. While hair overlying the scapulae may drop sideways, hair medial to the erector spinae muscles may move downwards and medially along the sweat crest. They will accumulate in the presacral and intergluteal area if there is more indigenous hair present. This "catching zone" will keep hair fragments at the lower border of the dorsal sweat crest and prolong their exposure to the healthy skin. Early removal though, may minimize exposure time and the amount of "successful" insertions [18, 19]. Whether cut hair can navigate beyond the elastic holding up underpants also remains to be shown.

Cut hair fragments have been found in PSD nests [12] and have been proven to come from the head [14]. The stiffer the hair, the higher the possibility that it is found in the sinus nest [13]. Thousands of cut hairs are produced with every head hair cut [15]. The results of this study suggest that cut hair from the head immediately follows a path down to the gluteal crest in substantial numbers. Whether this hair generates the pilonidal sinus, or if it just follows a previously formed fistula, is a still an open question.

CONCLUSION

With this evidence of the trail of cut hair translocation from head to gluteal fold, the next step is to validate these findings in a larger size study with clients that have a back cleansed from old cut hair right before the new haircut. This possible missing link to explain variable findings (i.e. associated risk factors) needs further evaluation. Almost everyone gets haircuts, but only a moderate (but increasing) number of mostly young men are at risk for PSD [20]. It is possible that the frequent exposure to many cut hair fragments at a certain age leads to pilonidal sinus disease. If we solve this question, then we can take the steps needed to prevent primary and recurrent PSD. In the meantime, taking a shower following each hair cut is a wise decision, especially between age 15 and age 25.

Cite this Article as: Doll D, et al. Pilonidal sinus disease is caused by cut hair translocation. PSJ, 2019. 5(1): 23 – 32. DOI:

ACKNOWLEDGMENTS

We acknowledge the editorial assistance of Jeannie Wurz, Science Writer in the Department of Anesthesiology and Pain Medicine, Inselspital, Bern University Hospital, University of Bern, 3010 Bern, Switzerland.

MULTIMEDIA

N/A

SUPPLEMENTAL

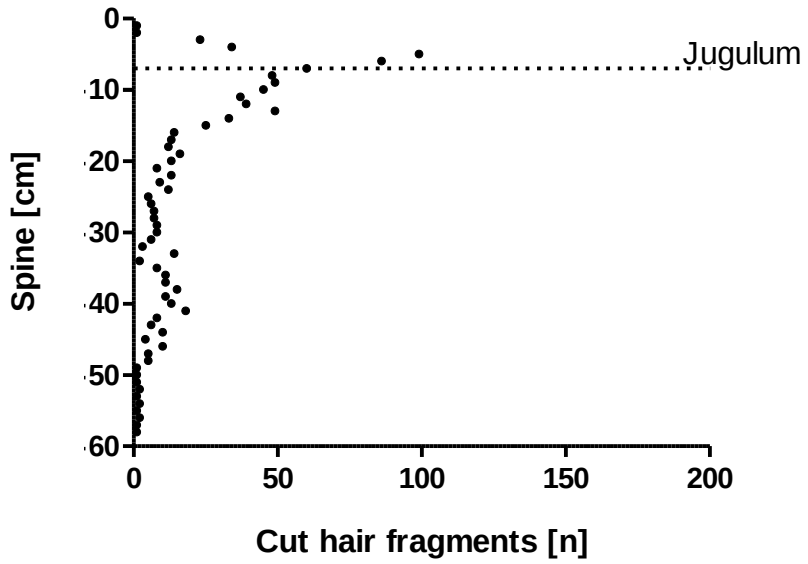

Supplemental Figure 2: Number of cut hair fragments at the front, ranging from jugular notch to the waist line in N=8 participants. Each dot in the graph describes the numbers of cut hair found in a horizontal segment 1 cm wide.

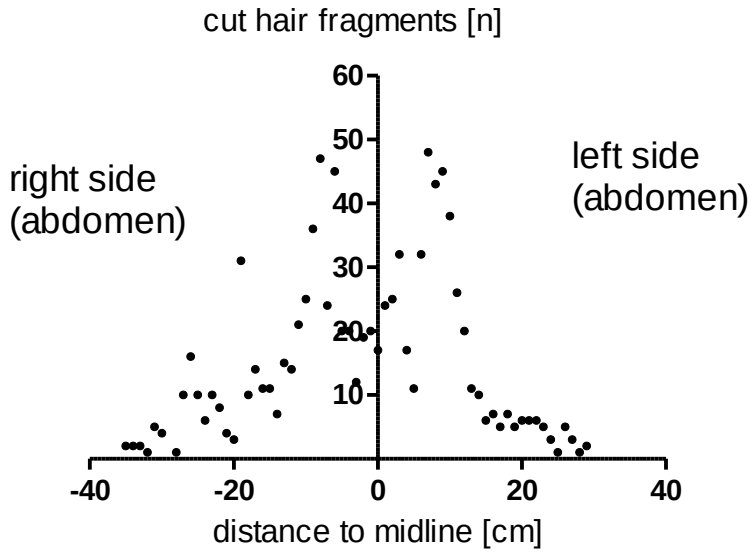

Supplemental Figure 3: Number of cut hair fragments at the front in and around the midline (N=8 participants). Each dot in the graph describes the numbers of cut hair found in a jugular notch-to-waistline segment 1 cm wide.

REFERENCES

1. Fox SL. The origin of pilonidal sinus with an analysis of its comparative anatomy and histogenesis. Surg Gynecol Obstet 1935;60:137.
2. Stone HB. Pilonidal Sinus: Coccygeal Fistula. Ann Surg 1924;79:410-4.
3. Davage ON. The origin of sacrococcygeal pilonidal sinuses based on an analysis of four hundred sixty-three cases. Am J Pathol 1954;30:1191-205.
4. Tourneur R, Dournovo P. [Pilonidal sinus: anatomo-pathologic study]. Gastroenterol Clin Biol 1977;1:923-4.
5. Mount LA. Congenital dermal sinuses as a cause of meningitis, intraspinal abscess and intracranial abscess. Journal of the American Medical Association 1949;139:1263–8.
6. Buie LA. Jeep Disease (Pilonidal Disease of Mechanized Warfare). Southern Medical Journal 1944;37:103-9.
7. Favre R, Delacroix P. [Apropos of 1,110 Cases of Pilonidal Disease of Coccy-Perineal Localization]. Mem Acad Chir (Paris) 1964;90:669-76.
8. Akinci OF, Bozer M, Uzunkoy A, Duzgun SA, Coskun A. Incidence and aetiological factors in pilonidal sinus among Turkish soldiers. Eur J Surg 1999;165:339-42.
9. Evers T, Doll D, Matevossian E, Noe S, Neumann K, Li HL, Huser N, Ludde R, Hoffmann S, Krapohl BD. [Trends in incidence and long-term recurrence rate of pilonidal sinus disease and analysis of associated influencing factors]. Zhonghua Wai Ke Za Zhi 2011;49:799-803.

10. Bascom J. Pilonidal disease: origin from follicles of hairs and results of follicle removal as treatment. Surgery 1980;87:567-72.
11. Lamke LO, Larsson J, Nylen B. Results of different types of operation for pilonidal sinus. Acta Chir Scand 1974;140:321-4.
12. Bosche F, Luedi MM, van der Zypen D, Moersdorf P, Krapohl B, Doll D. The Hair in the Sinus: Sharp-Ended Rootless Head Hair Fragments can be Found in Large Amounts in Pilonidal Sinus Nests. World J Surg 2018;42:567-73.
13. Doll D, Bosche FD, Stauffer VK, Sinicina I, Hoffmann S, Van der Zypen D, Luedi MM. Strength of occipital hair as an explanation for pilonidal sinus disease caused by intruding hair. Dis Colon Rectum 2017;60:979-86.
14. Doll D, Bosche F, Hauser A, Moersdorf P, Sinicina I, Grunwald J, Reckel F, Luedi MM. The presence of occipital hair in the pilonidal sinus cavity-a triple approach to proof. Int J Colorectal Dis 2018;33:567-76.
15. Doll D, Maier K, Albers K, Runden J, Massalis I, Moersdorf P, Vassiliu P, Luedi MM. Another common sharp hair fragment disease – barbers' anterior disease (BAD). Pilonidal Sinus Journal 2019:(accepted).
16. Phillips CW. Pilonidal disease in a military hospital. J Natl Med Assoc 1954;46:329-32.
17. Karydakis GE. Easy and successful treatment of pilonidal sinus after explanation of its causative process. Aust N Z J Surg 1992;62:385-9.
18. Harlak A, Mentes O, Kilic S, Coskun K, Duman K, Yilmaz F. Sacrococcygeal pilonidal disease: analysis of previously proposed risk factors. Clinics (Sao Paulo) 2010;65:125-31.
19. Bolandparvaz S, Moghadam Dizaj P, Salahi R, Paydar S, Bananzadeh M, Abbasi HR, Eshraghian A. Evaluation of the risk factors of pilonidal sinus: a single center experience. Turk J Gastroenterol 2012;23:535-7.
20. Stauffer VK, Luedi MM, Kauf P, Schmid M, Diekmann M, Wieferich K, Schnuriger B, Doll D. Common surgical procedures in pilonidal sinus disease: A meta-analysis, merged data analysis, and comprehensive study on recurrence. Nature Sci Rep 2018;8:1-27.